

Nervus opticus

Inhoud

Alleen over nervus opticus = N II = “papil”

- Verschillende ziekten N II
- 3 patienten met verschillende ziekten N II (klacht en live fundoscopie)
- Take home message


Verschillende ziekten (pathologie) N II

Algemene pathologie:

- Infarct
- Ontsteking

Oogheelkundige pathologie:

- Stuwling
- Glaucoom

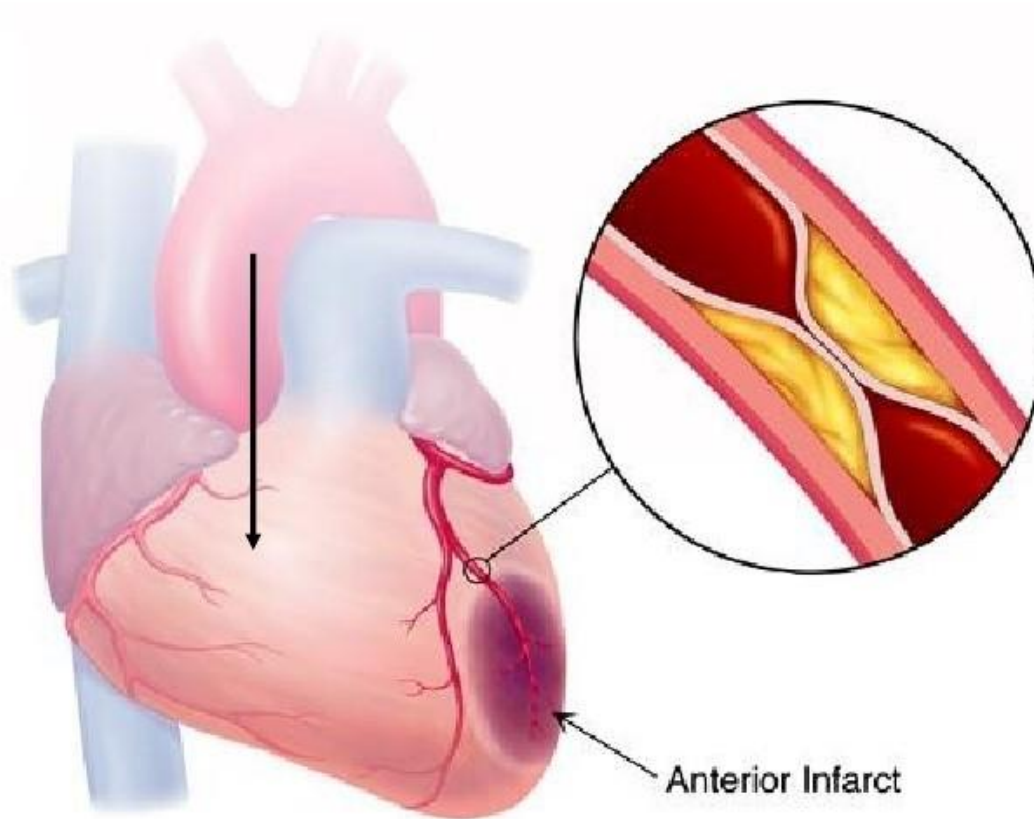


Oedeem
zenuwvezels

Verdwijnen
zenuwvezels

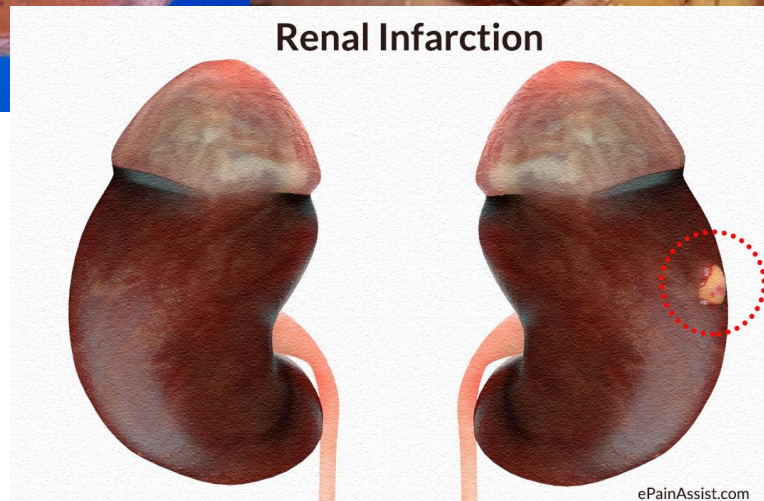
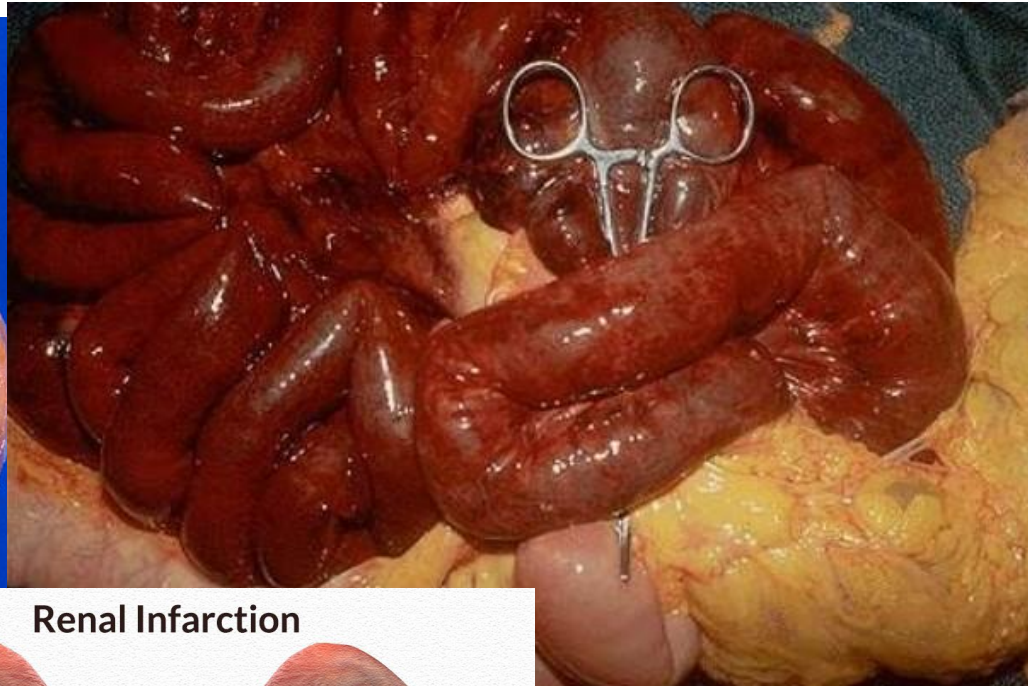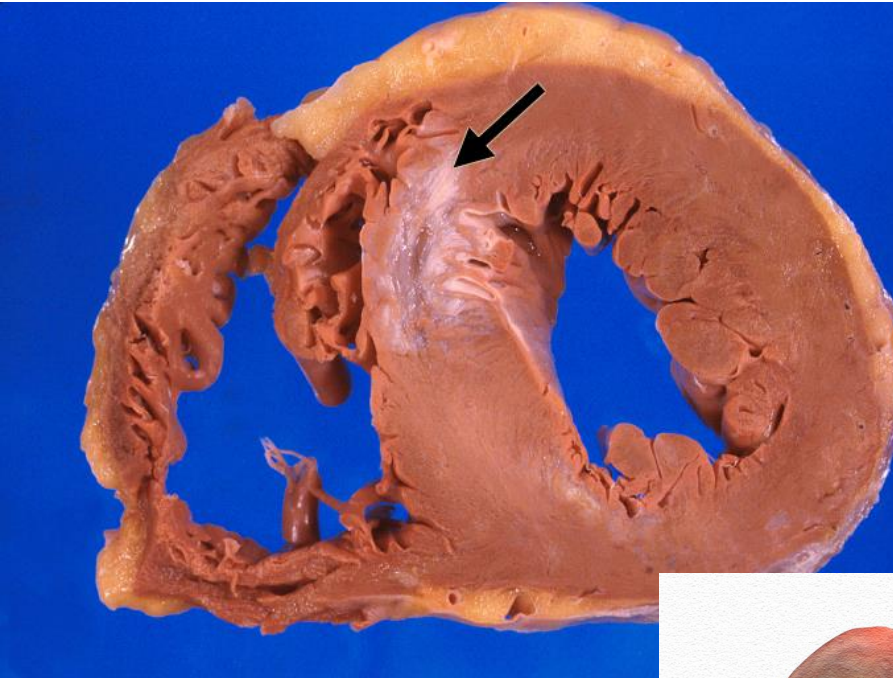
Verschillende ziekten (pathologie) N II

Infarct



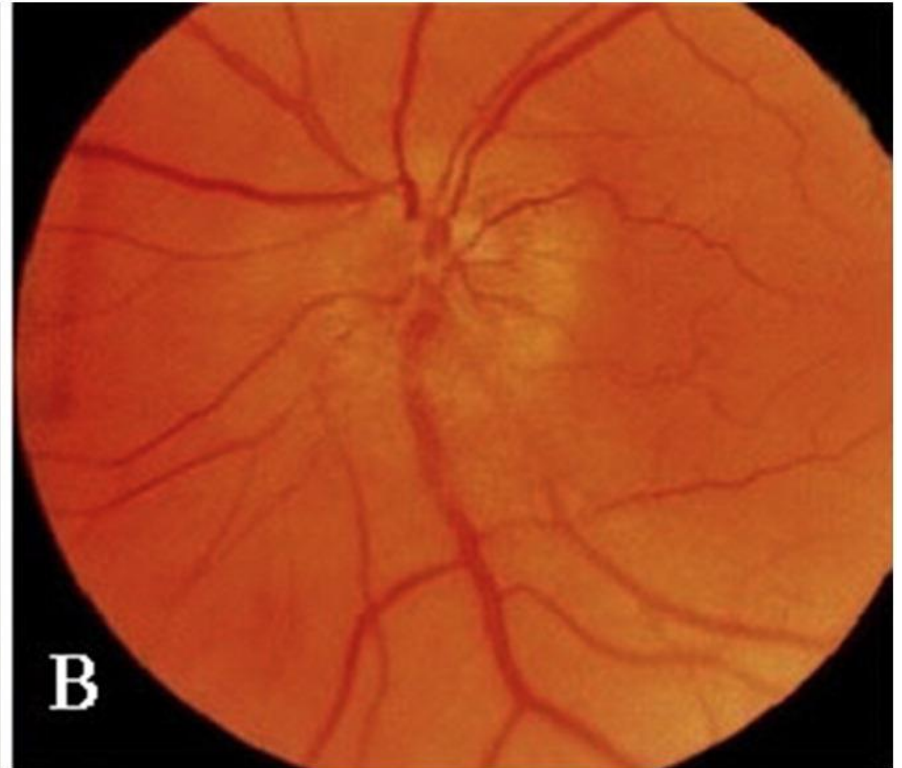
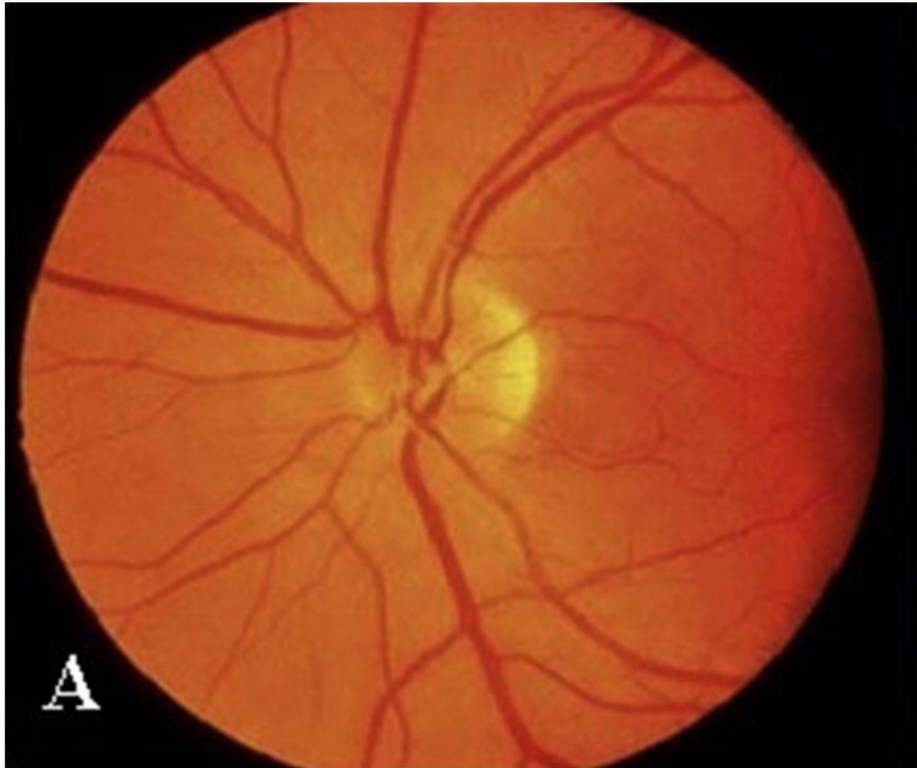Verschillende ziekten (pathologie) N II

Infarct



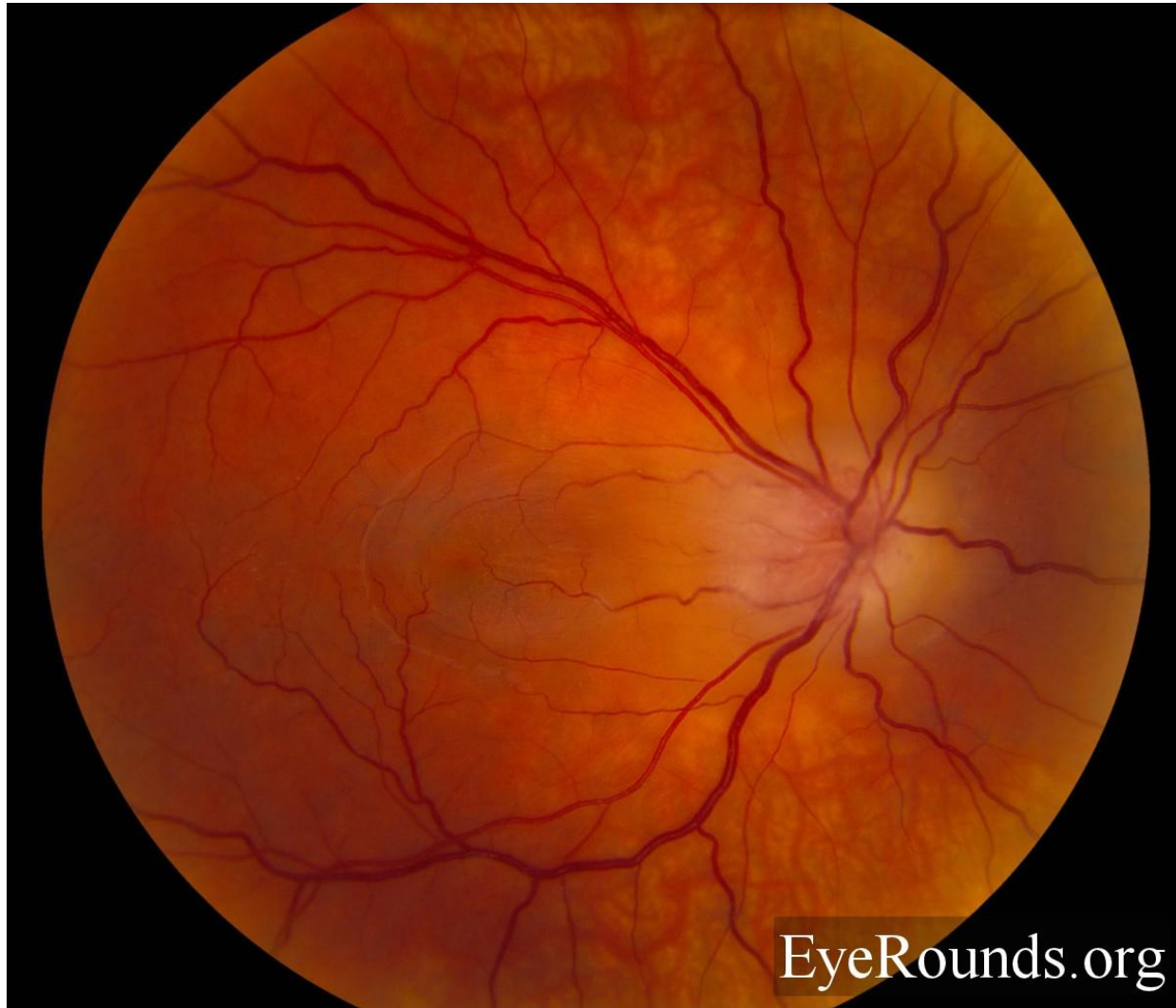
Verschillende ziekten (pathologie) N II

Infarct



Verschillende ziekten (pathologie) N II

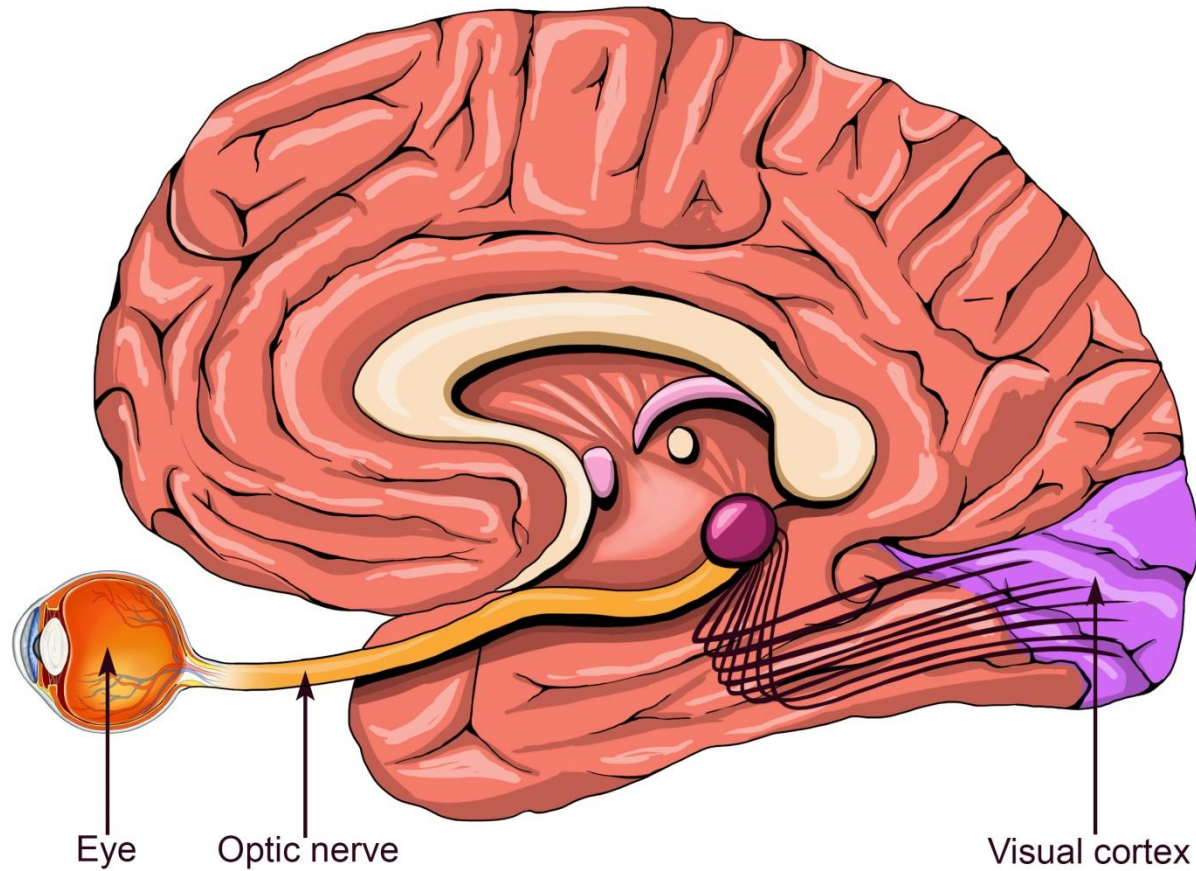
Ontsteking



EyeRounds.org

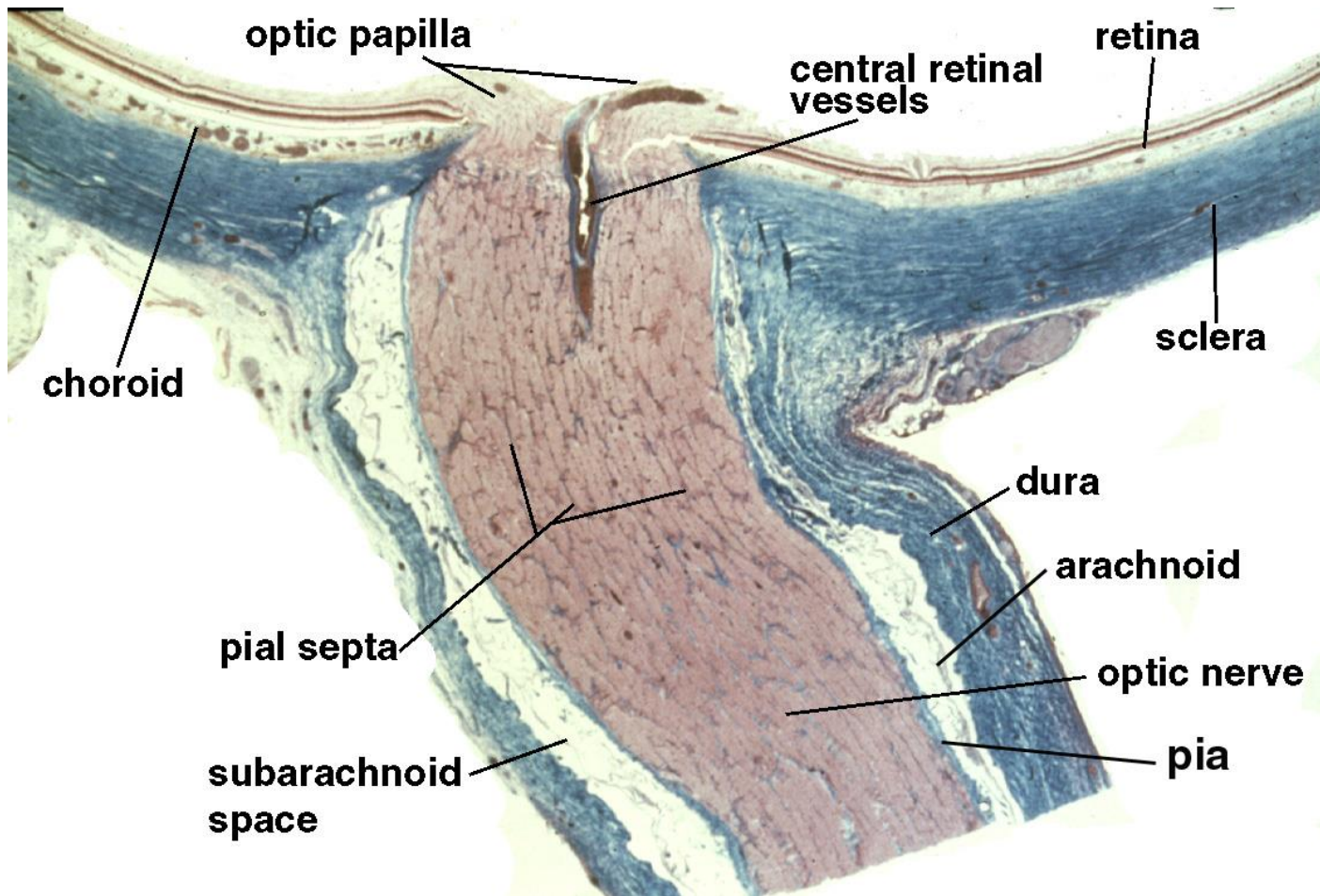
Verschillende ziekten (pathologie) N II

Stuwing



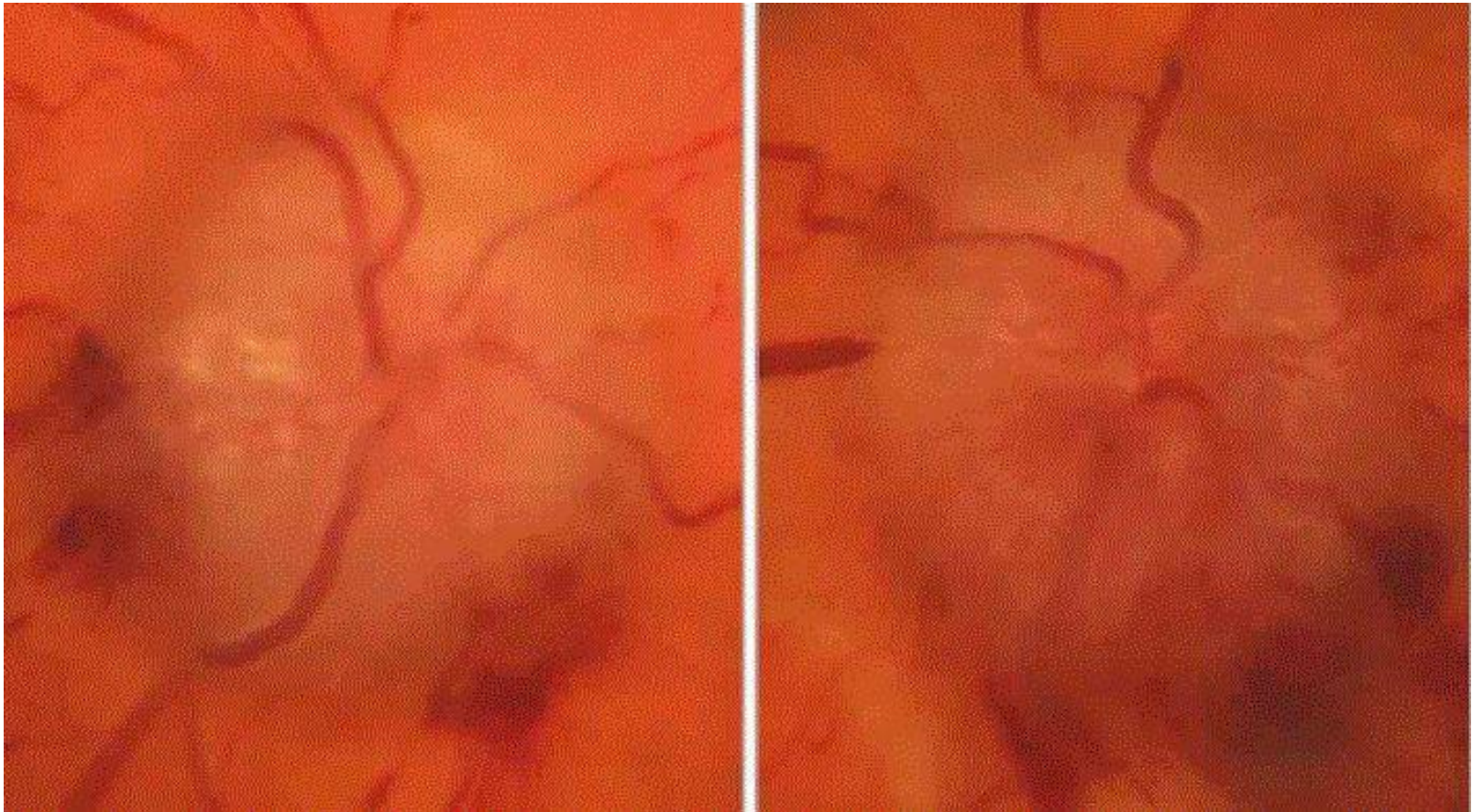
Verschillende ziekten (pathologie) N II

Stuwing



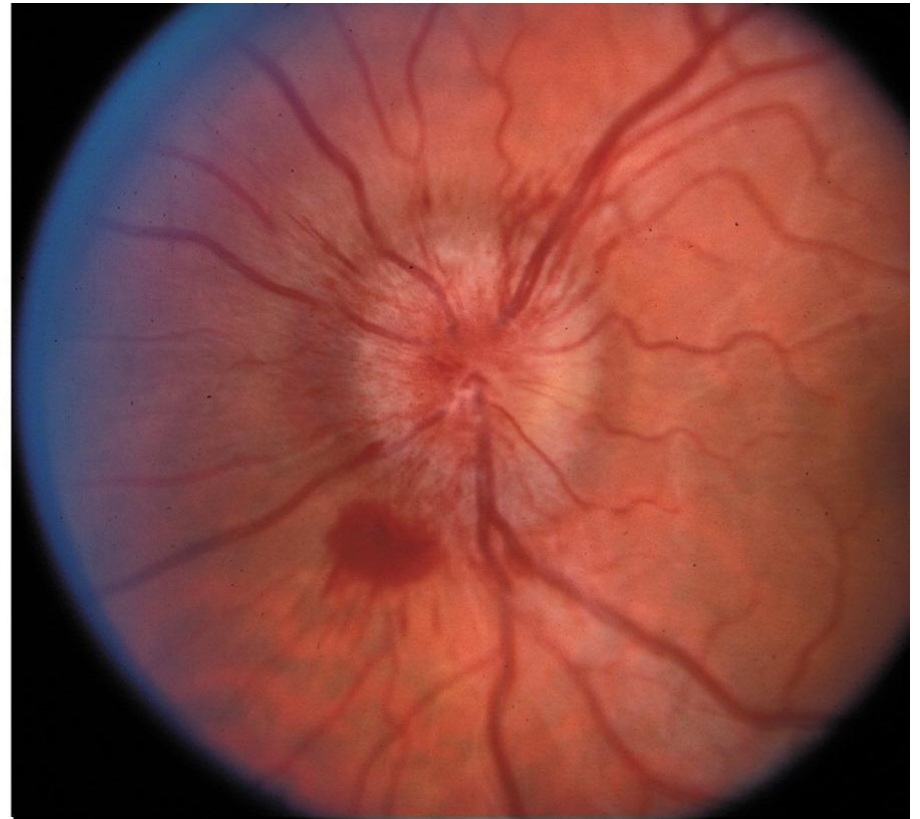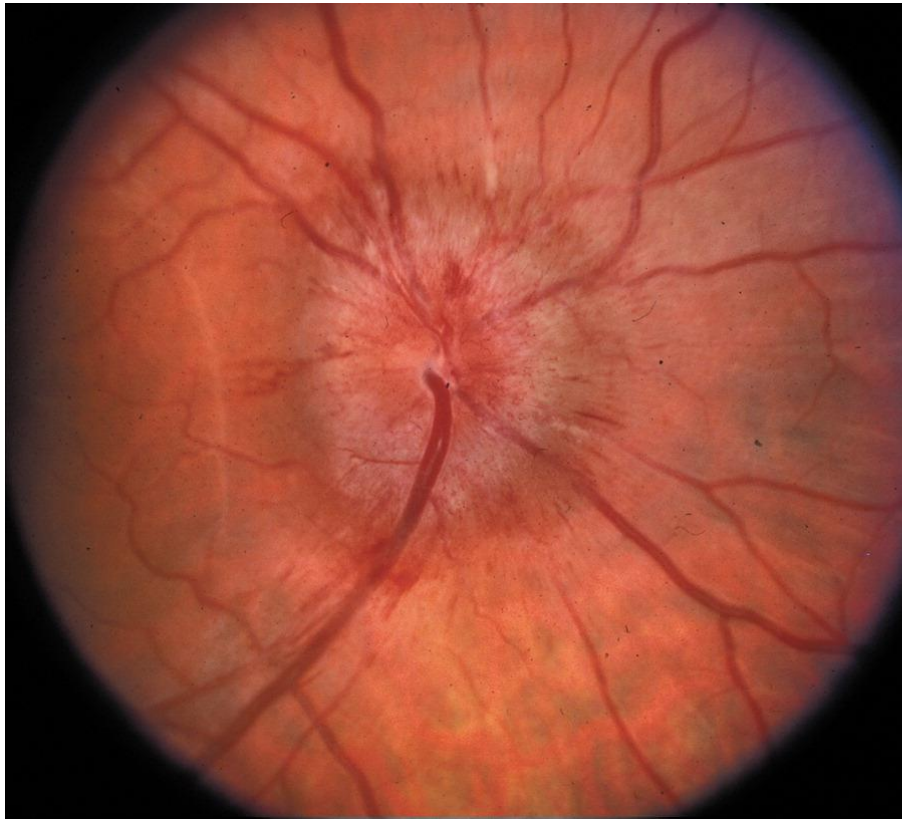
Verschillende ziekten (pathologie) N II

Stuwing



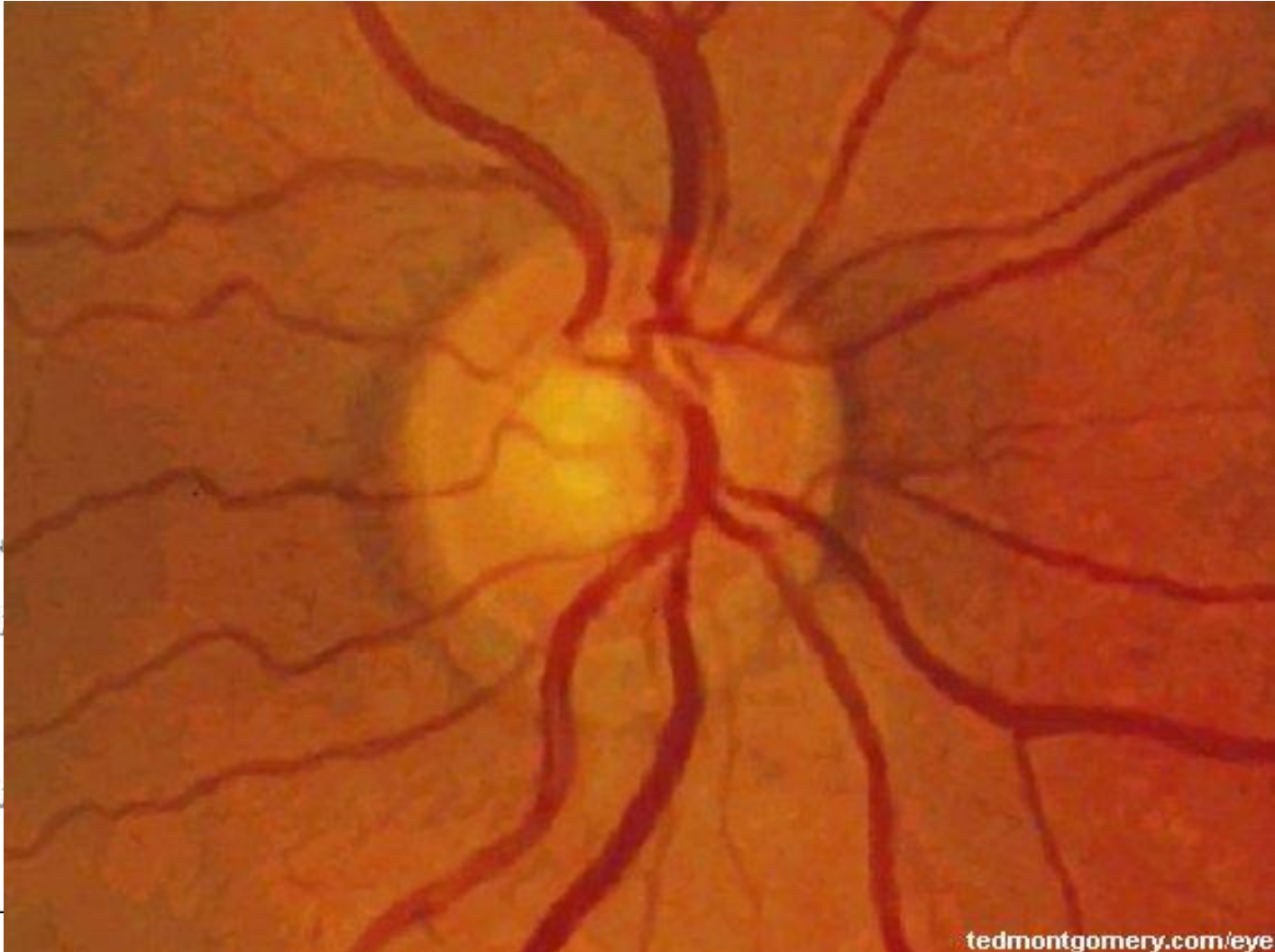
Verschillende ziekten (pathologie) N II

Stuwing




Verschillende ziekten (pathologie) N II

Glaucoom

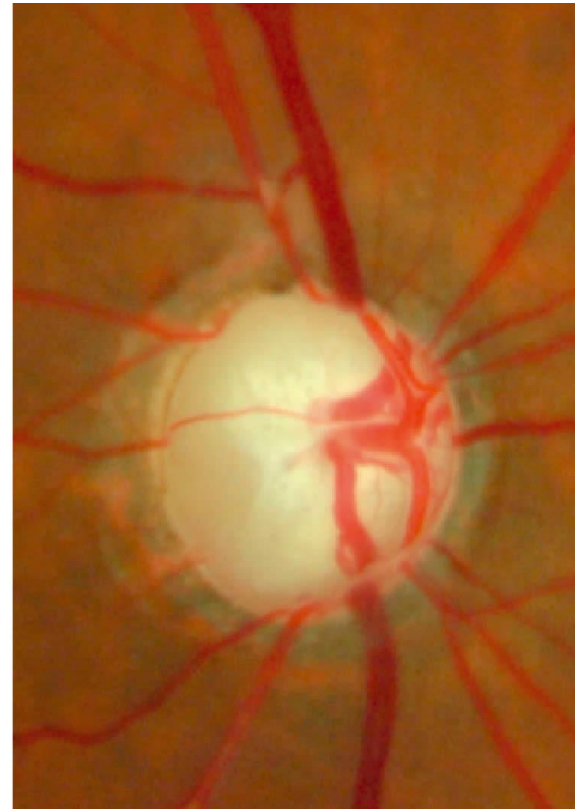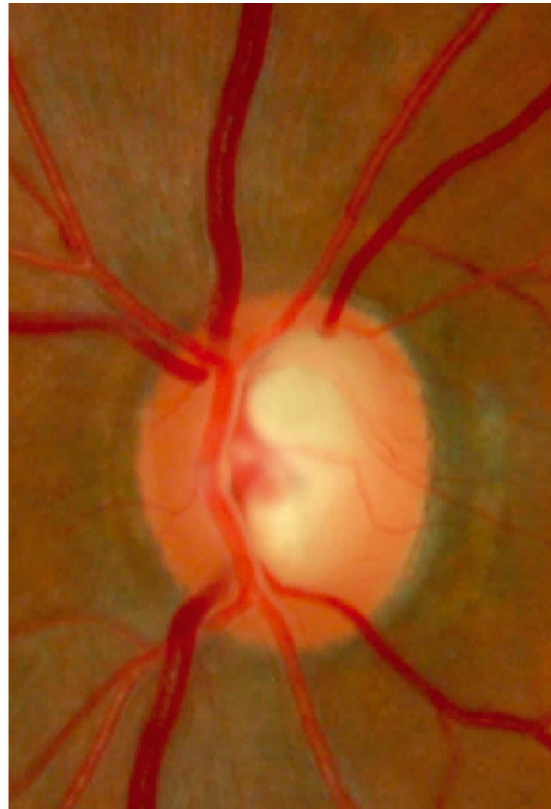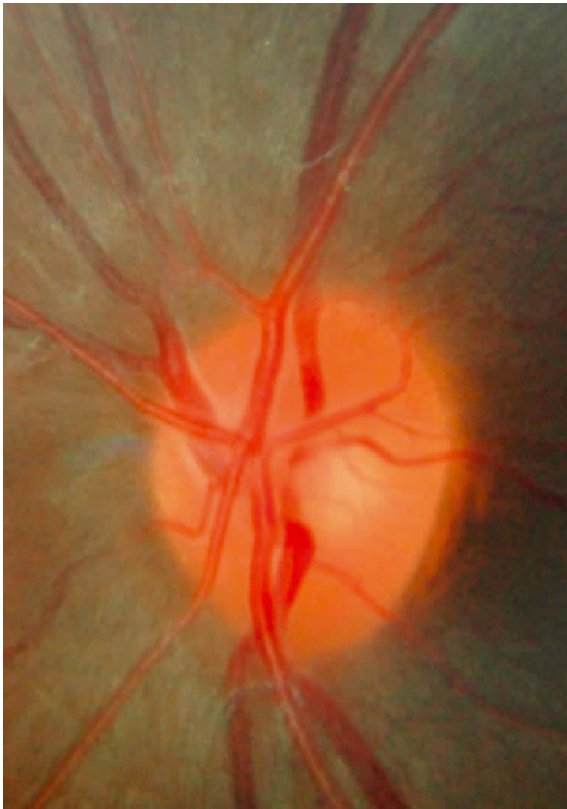


Verschillende ziekten (pathologie) N II

Glaucoom



Verschillende ziekten (pathologie) N II Glaucoom



3 patienten met verschillende ziekten

N II

1 2 3



Take Home Message

Unilaterale visusdaling en visus minder dan 0.5



RAPD testen

Vóórdat je mydriasis geeft!